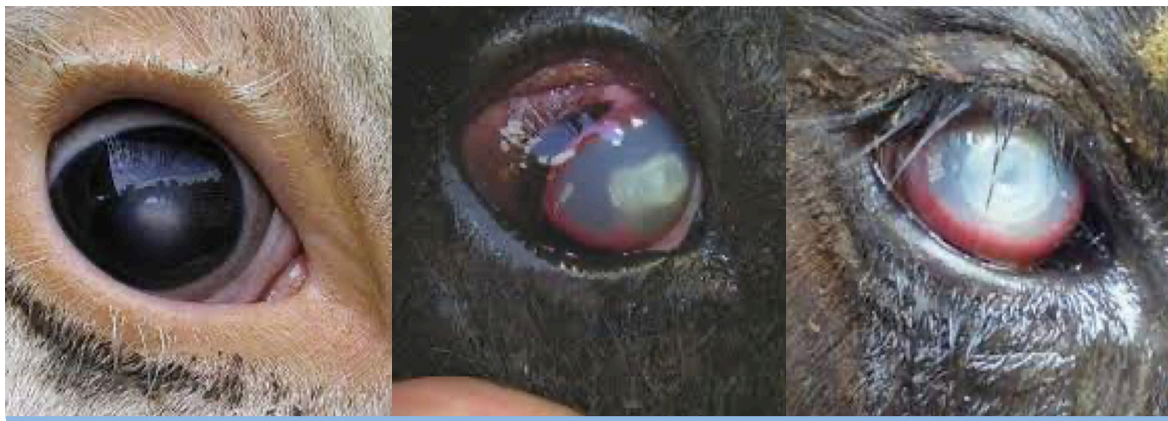



APPEARANCE

TREATMENT


PINK EYE

- Usually occurs in summer.
- Cloudy appearance to eye.
- Starts as a circular spot in centre of eye.
- Progresses to ulceration of the cornea.
- Eyelids partially closed (light sensitive).
- Tear-staining on face.

- Orbenin Eye Ointment, ½ tube, repeat in 48hours if necessary.
- Ketomax
- It will take some time for the cloudiness to disappear.

PROGNOSIS

- Good if identified early, poor if severely ulcerated.
- It will take some time for the cloudiness to disappear in mild-moderate cases. Severe cases will remain cloudy with potential for loss of eyesight.



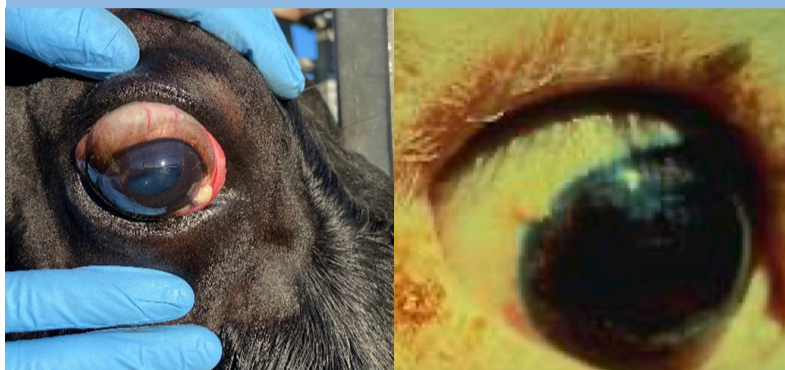
THIRD EYELID

- The third eyelid starts from the inside corner of the eye.
- Third eyelid becomes more prominent.
- Wart-like growth on membrane
- Can be inflamed, red, discharge.
- May also ulcerate.

- Vet examination
- Third eyelid removal if confined to the third eyelid

PROGNOSIS

- Good if growth is confined to third eyelid.
- Potential for spread if left untreated.



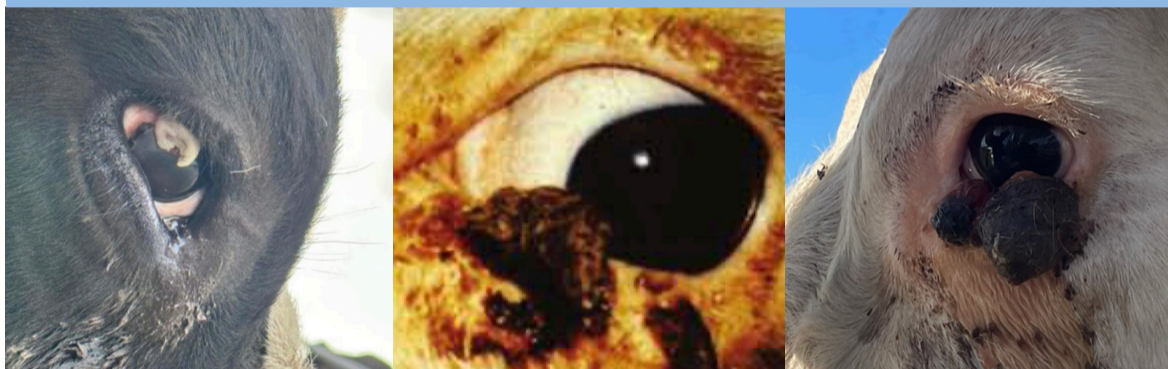PLAQUES

- Small circular, white-ish, raised growth on the surface of the eye, usually at the junction between white and coloured parts of the eye.
- Benign growth, can become malignant.

- Vet examination
- Cryosurgery if <1cm in diameter

PROGNOSIS

- Good if removed early.
- Usually benign growths that can become malignant.



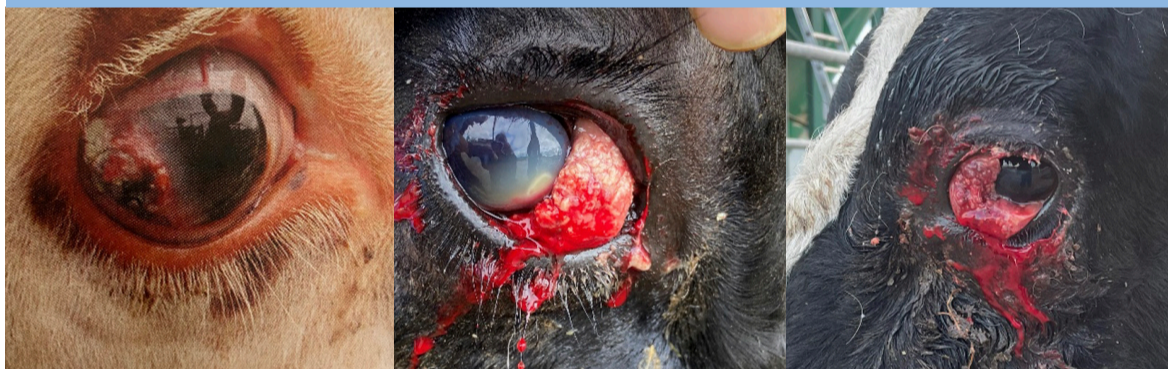
KERATOMA

- Attached to eyelid
- Irregular shape, horny edges
- Often with discharge and debris
- Benign growth

- Vet examination
- Cryosurgery if <1cm in diameter
- Eye removal if larger size

PROGNOSIS

- Usually benign growths but can become large causing irritation to eye and preventing closure of eyelids.



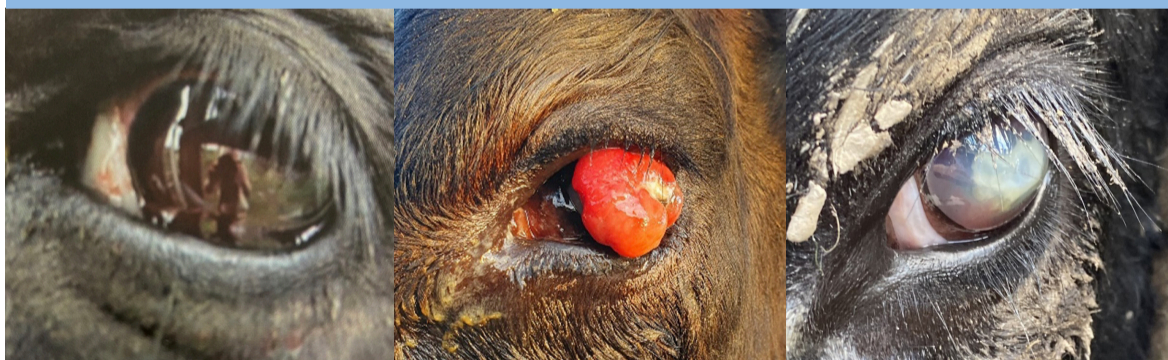
EYE CANCER

- Fleshy cauliflower appearance on third eyelid extending to surface of eye.
- Often easily bleeds.
- Malignant growth

- Vet examination to confirm for spread to lymph nodes or bone.
- Eye removal OR cull
- See transport regulations below.

PROGNOSIS

- Depends on size of growth. Good with early removal of the eye.



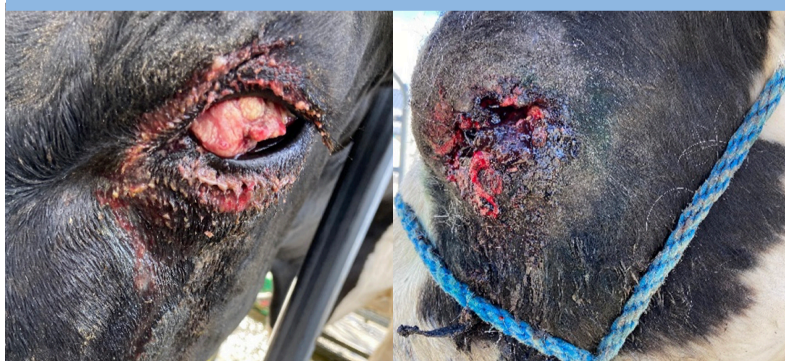TRAUMA

- Redness behind surface of eye.
- Contents of eye prolapsed.
- Ulceration to surface of the eye.
- Enlarged, unable to close eyelids.
- Eyesight may be unsalvageable in advanced cases.

- Vet examination to confirm if treatment required.
- Ketomax
- Eye removal (depending on severity) OR Cull
- Advanced cases cannot be transported.

PROGNOSIS

- Depends on severity. Eyesight may be unsalvageable in advanced cases.



HOPELESS CASES

- Significant cancerous growth over eye surface, prolapsed or infected eye.
- Bleeding, infected, swollen, unable to close eyelids.
- Malignant growth likely spread to other areas of body.

- Humane destruction
- Pet food
- These cases cannot be transported.

PROGNOSIS


- Poor

If in doubt, contact your key vet. Seek vet advice if initial treatments are not improving after 2-3 days.



Transport regulations prevent transporting animals if:

- cancer is larger than 2cm in size (\$1 coin)
- cancer is no longer confined to the eye or eyelid
- any bleeding or discharge
- blindness in both eyes
- pink eye with pus



If animal is not fit for transport:

- Seek veterinary advice for treatment on farm
- Humane euthanasia
- Contact pet-food processor

